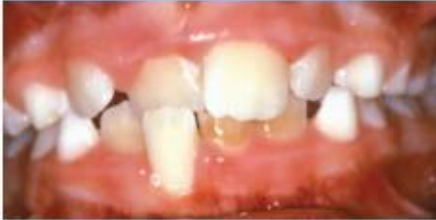

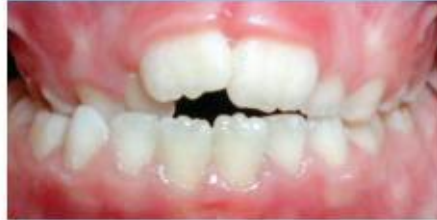Problems to Watch for in Seven Year Olds

Malocclusion like those illustrated below, may benefit from early diagnosis and referral to an orthodontic specialist for a full evaluation.

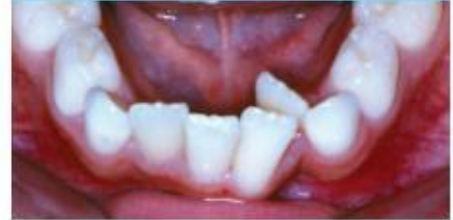Anterior Crossbite



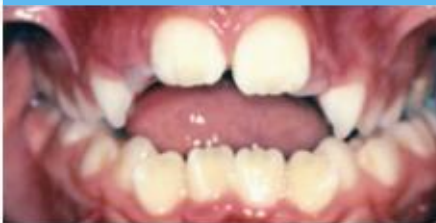Posterior Crossbite



Crowding

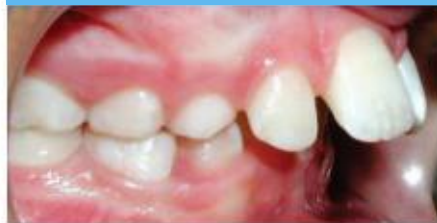

Open Bite

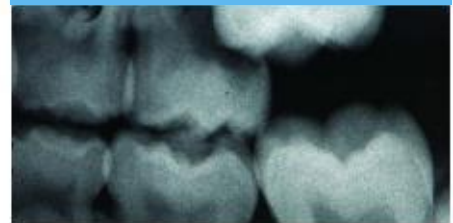


An open bite is usually due to an oral habit

Protrusion

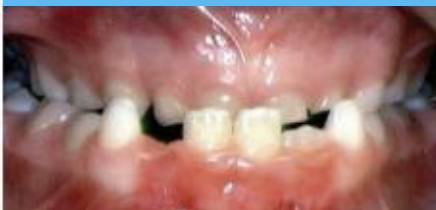

Ectopic Eruption

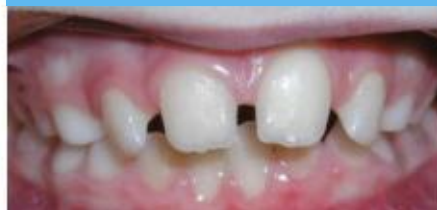

Ectopically erupting maxillary molar

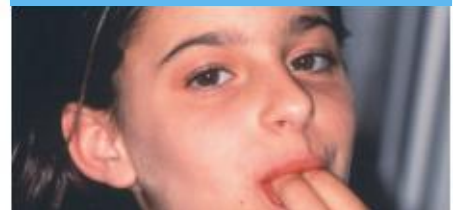Complete Class III



Diastema



Oral Habits



If you notice any of the following in your child, check with your orthodontist:

- Early or late loss of baby teeth
- Difficulty in chewing or biting
- Mouth breathing
- Jaws that shift or make sounds
- Biting the cheek or the roof of the mouth
- Facial imbalance